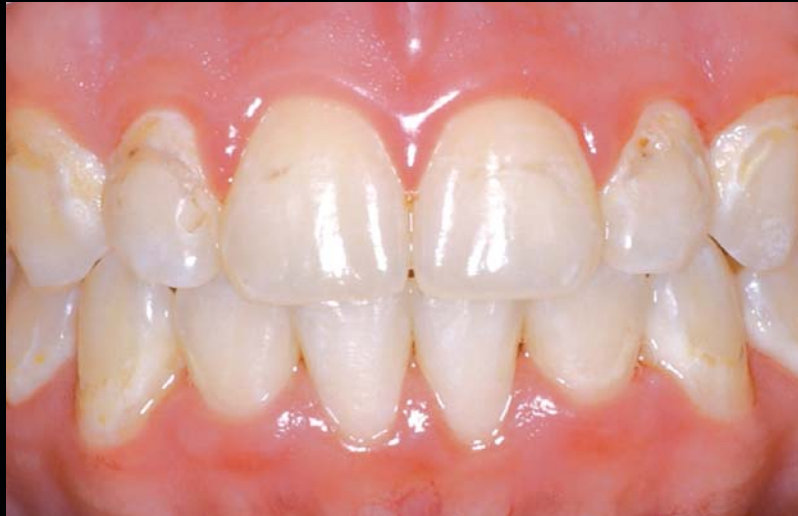

MINIMALLY INVASIVE RESTORATIVE DENTISTRY: A BIOMIMETIC APPROACH

Mark I. Malterud, DDS*



When providing dental treatment for a given patient, the practitioner should use a minimally invasive technique that conserves sound tooth structure as a clinical imperative. Biomimetics is a tenet that guides the author's practice and is generally described as the mimicking of natural life. This can be accomplished in many cases using contemporary composite resins and adhesive dental procedures. Both provide clinical benefits and support the biomimetic philosophy for treatment. This article illustrates a minimally invasive approach for the restoration of carious cervical defects created by poor hygiene exacerbated by the presence of orthodontic brackets.

Learning Objectives:

This article discusses minimally invasive procedures for treating and restoring damaged teeth due to cavitated carious lesions. Upon reading this article, the reader should:

- Become familiar with a variety of treatment options that are available and their varying levels of invasiveness.
- Understand the importance of conserving as much natural tooth structure as possible and how this can benefit subsequent treatments.

Key Words: biomimetics, minimally invasive, composite resin, natural, anterior, microhybrid, demineralization

*Private practice, St. Paul, MN.

Mark I. Malterud, DDS, 770 Mount Curve, St. Paul, MN 55116
Tel: 651-699-2822 • E-mail: mark@drmalterud.com

It is generally accepted by dental practitioners that prevention is the most conservative, least costly method of maintaining their patients' teeth over the long term.^{1,2} Prevention has been the cornerstone of modern dentistry, but even with the encouragement and education provided by a trained staff, clinicians will encounter some patients who present with compliance issues. Many times, compliance with home care—especially during orthodontic treatment—is neglected, and teeth must be restored with invasive procedures.

The severity of the resulting damage can often be seen in the form of extrinsic stains (ie, white spot surface lesions), as well as cavitated carious lesions.³ These lesions, which are caused by the accumulation of plaque and bacteria,^{4,5} can be addressed through treatments of varying invasiveness. Depending on the severity of the lesion and its etiology, therapy may consist of prophylaxis, air abrasion, tooth whitening, resin bonding, prosthetic restoration, or some combination thereof. The treatments described herein are not meant to serve as a definitive treatise on how to handle dental caries manifested during orthodontic treatment, but rather to share one practitioner's experience in satisfying specific restorative needs of the patient by providing minimally invasive treatment.

Minimally invasive treatments are procedures that restore form, function, and aesthetics with minimal removal of sound tooth structure.^{6,8} As a person ages, so do their restorations. Eventually, teeth that have been restored will break down and need to have those restorations replaced.^{9,10} Fortunately, restorative materials and procedures are constantly evolving. If an initial restoration was created using minimally invasive procedures, there should be more tooth structure to work with at the time that a second restoration may be needed. A scenario like this is shown in the following case presentation.

Case Presentation

Following orthodontic treatment, a 15-year-old female presented for evaluation and treatment of the demineralized lesions present on most of her teeth (Figure 1). The patient's chief complaint was the unaesthetic appearance created by the lesions around and beneath the orthodontic brackets she had worn. After a thorough clinical examination was performed and radiographs were taken, a treatment plan was formed. Using a

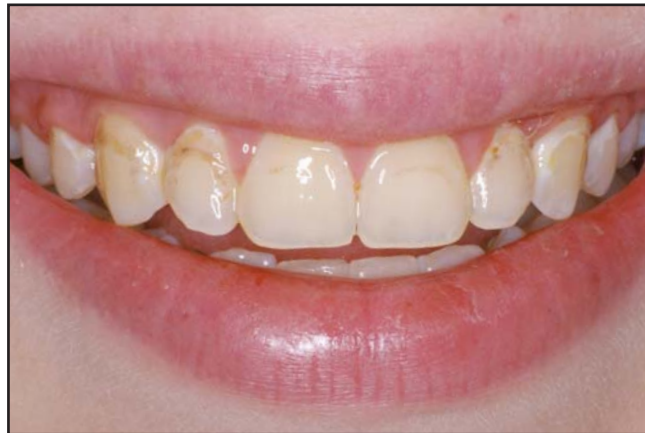

Figure 1. Preoperative smile. Note the significant amount of demineralized teeth, orthodontic bracket scars, and poor gingival health.

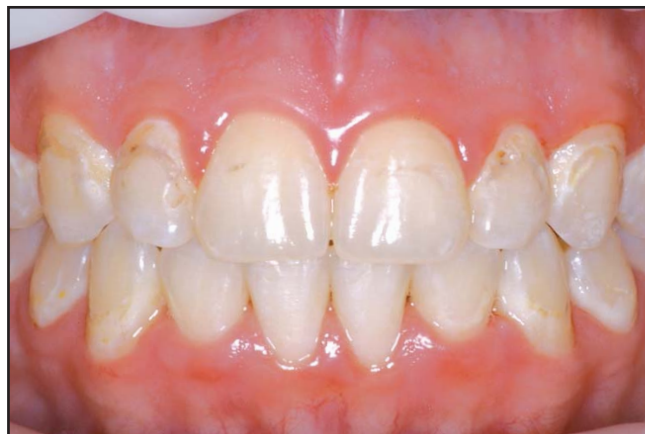

Figure 2. Tissue edema and erythema remain around the gingival aspect of the maxillary anterior teeth after two months of increased home hygiene and MI paste use for the demineralized areas.

minimally invasive approach, the clinician would first prescribe the use of a remineralization toothpaste to repair the demineralized enamel.¹¹ Should this manner of treatment prove insufficient to produce the required outcome, additional minimally invasive procedures would be undertaken.

The Initial Hygiene Protocol

During a subsequent hygiene visit, the patient was once again instructed on the use of a toothbrush and dental floss. As part of the hygiene regimen, the patient also received instruction on the application of a remineralizing paste (ie, MI Paste, GC America, Alsip, IL) that would provide active calcium and phosphate to repair the

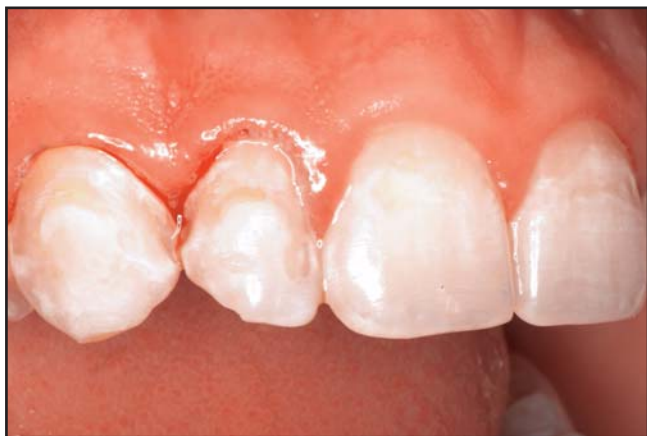

Figure 3. Air abrasion preparations on teeth #6(13) through #9(21) show gingival hemorrhaging in the unhealthy gum tissues. Lesions on teeth #6 and #7 extend interproximally.

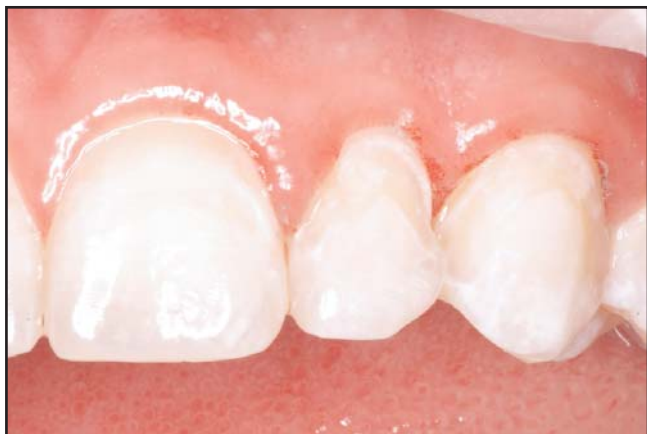

Figure 4. Preparations of teeth #9 through #11(23) showing minor tissue hemorrhaging. Teeth #10(22) and #11 show the interproximal extension of the preparation.

damage of the demineralization and to prevent the need for future restorations. Follow-up appointments revealed that many of these demineralized areas were adjacent to tissues that did not respond well to the patient's home care regimen.

Consequently, the decision was made to restore the porous decalcified tooth structure and to create a smoother tooth surface that would retain less plaque and be easier to clean. Controlling the tissues, which were weeping sulcular fluids, could be accomplished in a number of ways that would not compromise the bonds to the tooth structure. As a number of lesions had cavitated beyond the possibility of remineralization, the author opted to place minimally invasive restorations in the

cavitated lesions of teeth #6(13) through #11(23) and #27(43) (Figure 2).

Minimally Invasive Restorative Care

Selected as the next treatment to follow this minimally invasive philosophy was air abrasion.⁶ This process was utilized to selectively remove the carious lesions and demineralized enamel and to establish a substrate that would be conducive to subsequent adhesive bonding procedures.^{12,13} Tissues were retracted in the few places where the lesion extended subgingivally. The method used by the author was a simultaneous spray of aluminous oxide air abrasion particles and copious amounts of water. This technique creates a parallel water stream with the air abrasion particles and accomplishes two things. First, it minimizes aspiration as the moist air abrasion particles are suctioned up in the HVE, and secondly, it makes the stream of particles more effective at removing softened tooth structure. Experience with air abrasion lets users know that they need to angle the air abrasion particles at the tooth and away from the gingiva, thus minimizing both trauma and embedding aluminous oxide into the tissues. To be sure that all caries were removed, a sharp explorer and an extremely sharp titanium nitride-coated microspoon excavator were used. The tactile approach taught at most dental schools today was utilized. As observed in the final preparations (Figures 3 through 5), the design did not follow any conventional forms.

Isolation of the lesions was crucial to the success of the bonding process. Much of the demineralized areas of the teeth were adjacent to gingival tissues that were not very healthy at the time of preparation. Considering this, applying a rubber dam would have been more cumbersome than performing single-tooth isolation, which was accomplished utilizing a contoured Mylar matrix strip (ie, Contour Strip, Ivoclar Vivadent, Amherst, NY). The contour strips are three-dimensionally shaped to encircle the tooth by rolling them between the thumb and index finger. They are then flared at the gingival with the cone end of a cone-socketed hand instrument. This technique not only created a cervical seal but also helped establish an optimal emergence profile. This procedure was more efficient than using a #212 clamp placed on the tooth being restored as it causes much more tissue trauma. The contour strip, meanwhile, completely isolates the work area as it created the emergence profile, which generally cannot be detected with an explorer

postoperatively. The result is the smoothest profile the composite offers. The composite is polymerized against a Mylar strip and does not require finishing if matrixed appropriately. If it were possible to view the subgingival area, it would be seen that a curve is created at the gingiva during the shaping of the contour strip. This virtually recreates the CEJ and is placed at the point where it will hold and protect the tissues, just like the original CEJ.

The subgingival placement of the margins of the restoration and the selective contouring of the strip created a surface that would support long-term gingival health (Figure 6). The portion of the gingival composite built up against the Mylar strip had an extremely smooth surface without an oxygen-inhibited layer, so polishing of this area was unnecessary. The contoured Mylar strips were trimmed and placed around the facial and proximal surfaces of the tooth and sealed in place with an unfilled resin (ie, Heliobond, Ivoclar Vivadent, Amherst, NY; Cannulas, Ivoclar Vivadent, Amherst, NY) that was also placed on the gingival surface of the strips to stabilize them (Figure 7).

Once the matrix form was in place, the bonding process could proceed. A 37% phosphoric acid etchant was placed on the prepared lesion for 15 seconds,¹³ rinsed for 20 seconds, and lightly air dried. The etch was placed on the enamel first and then spread onto the dentin so that the dentin exposure time is far less. Rinsing time ensures a clean and neutralized surface. Leaving the bonding agent (ie, PQ1, Ultradent, South Jordan, UT) on for 30 seconds assures that there is an adequate hybrid zone. This allows the proper penetration of the resin to occur. With the area matrixed exactly where

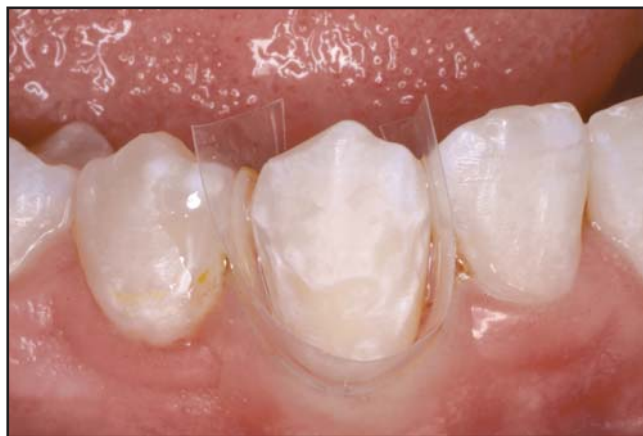

Figure 6. Individual isolation of tooth #27 utilizing a custom contoured Mylar strip secured to the tooth and gingiva with unfilled bond resin.

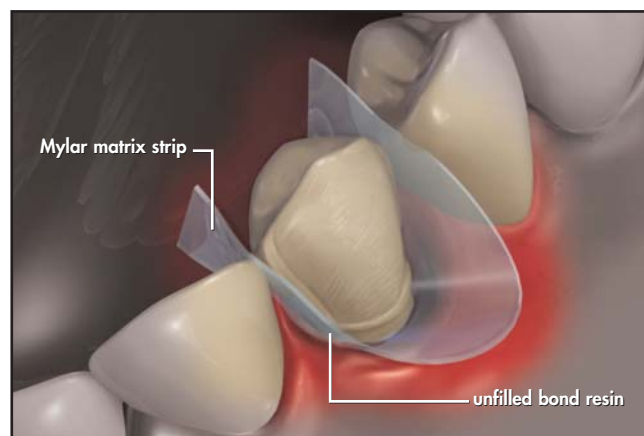


Figure 7. Illustration of the Mylar matrix strip securely placed subgingivally and stabilized with unfilled bond resin.

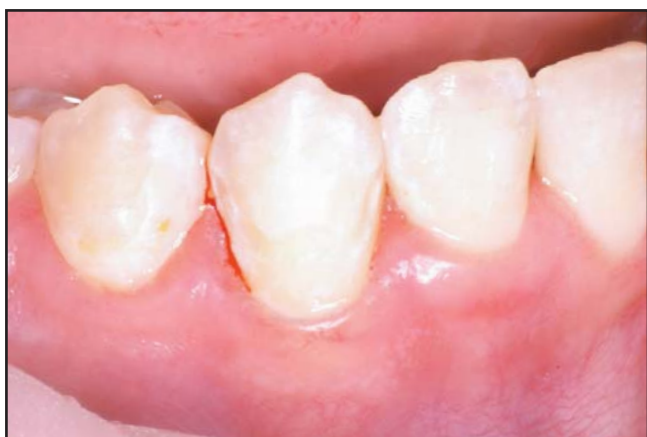

Figure 5. Preparation of tooth #27(43) showing subgingival extension of the preparation, which will require isolation for restoration.

the final margins should be, the prepared and etched tooth structure was coated with a bonding agent. This adhesive thoroughly wet the dentin and would allow the composite resin to penetrate into the tooth; it would also remove any excess intertubular fluids and create the hybridized zone. After thinning the bonding agent with a steady stream of dry air, the entire bonded surface was light cured for 30 seconds. The appropriate dentin-shaded resin (A1) was placed into the deep dentin portions of the preparations and polymerized. The final layer of enamel-shaded composite resin (T1) was placed to create the full contour and the surface translucency of the restoration. Each tooth involved in this single appointment, direct procedure was independently isolated and

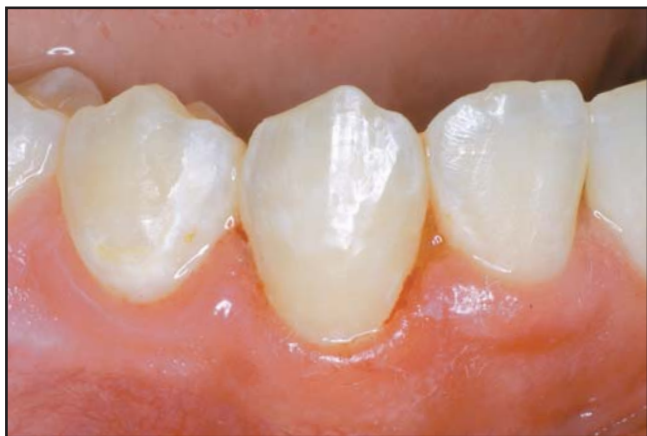

Figure 8. Immediate postoperation of matrixed tooth #27 showing minimal tissue trauma and a life-like match of the emergence profile, tooth contour, and color.

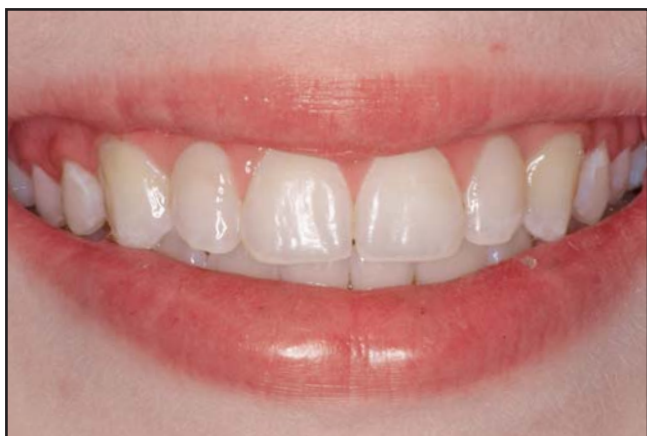

Figure 9. One-week follow up of the patient's smile. The gingival health has improved.

restored utilizing these steps. Bands were placed simultaneously on each independent tooth and then removed simultaneously as well.

After the composite resin had been brought to full contour and was thoroughly polymerized, the matrix was removed, and the final shaping, surface texturing, and polishing was completed, ensuring that the teeth would match the unprepared tooth (Figure 8). Due to the inherent polishability of the microhybrid composite selected, these restorations were shaped and polished using primarily two burs. A 30-fluted flame-shaped bur was used to create the contours and textures; the final polish was rendered with a fine-polishing rubber point (ie, Astropol, Ivoclar Vivadent, Amherst, NY). By matrixing with the

contour strips, subgingival polishing is not generally necessary, and the points and cups are efficient. The Astropol cups (Ivoclar Vivadent, Amherst, NY) have a thin lip that, if needed, enables them to be pressed onto the tooth and consequently flared, allowing for some subgingival polishing. The surface luster was buffed to the prerestored luster of this patient's buccal tooth structure.

Follow-up and Maintenance

As observed in one- and two-week follow-up visits, there was an excellent gingival response to the polished restorations (Figures 9 through 12). With conscientious home care, these restorations that were created according to minimally invasive restorative protocols, should provide years of enjoyment for the patient. Each tooth has been effectively restored to good form, function, and aesthetics. If the patient decided at a later point in her life to pursue additional aesthetic enhancement, porcelain laminate veneers can be considered once the gingival tissues have matured and home care remains consistent. Therefore, mimicking nature as a clinician helps direct patients toward better dental health, allowing them time to heal and learn appropriate skills for their personal dental hygiene.

Discussion

Air abrasion is an effective process that the clinician can use to remove demineralized enamel and the underlying carious dentin.^{14,15} In the author's experience, air abrasion also creates an ideal surface for achieving excellent bond strengths to both dentin and enamel.^{12,13} The various air abrasion units currently on the market use

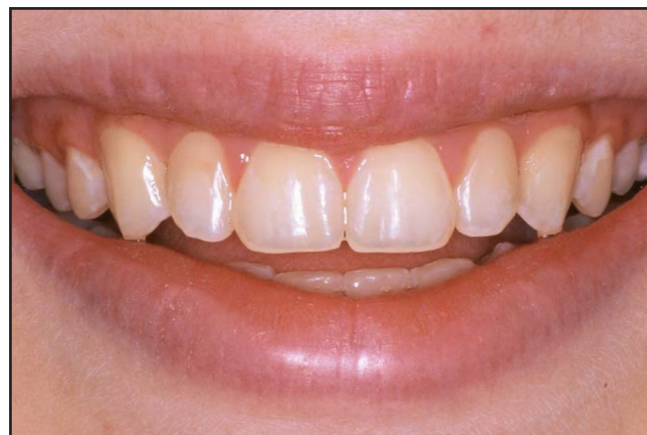

Figure 10. Two-week follow up. Gingival health has been restored.

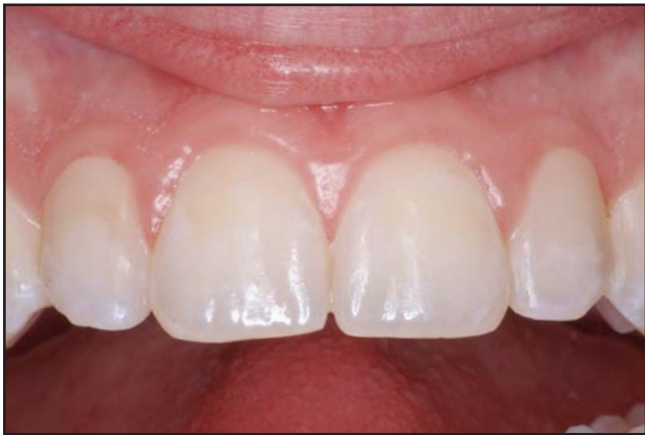

Figure 11. Gingival tissue health at two weeks is remarkably better.

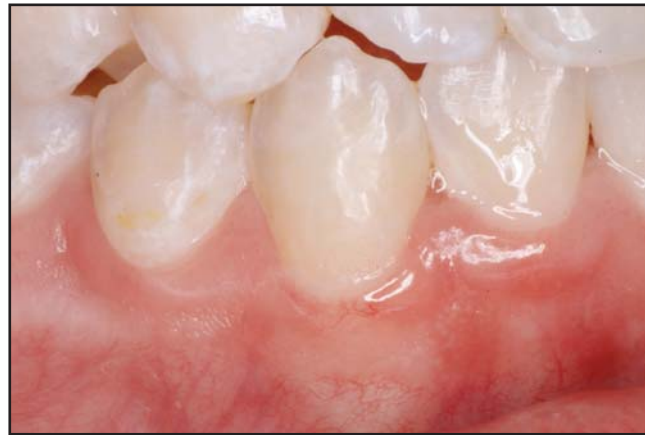

Figure 12. Tissue health at two weeks is markedly improved.

aluminous oxide powder and a water stream to selectively remove demineralized enamel and carious dentin. Very often, teeth can be prepared, as described in the aforementioned adhesive bonding procedure, via air abrasion without the need for anesthesia, especially when used with the water spray. The simultaneous delivery of the aluminous oxide and warm water keeps the scatter of aluminous oxide powder to a minimum.

The microhybrid composite resin (ie, Venus, Heraeus Kulzer, Armonk, NY) was selected as the restorative material of choice for replacing the missing tooth structure because of its ability to match the shade and translucency of the adjacent tooth structures. The physical properties (eg, fracture toughness, flexure modulus, wear resistance) and polishability of the microhybrid resins also make them suitable treatment options for the use of such indications as described previously.^{16,17} Additionally, utilizing the unit-dose or preloaded tips for the individually matrixed teeth enabled effective placement of the composite, as the material could be injected into the shapes created by each matrix.

Conclusion

Preventive dental maintenance is the most cost-effective means of preserving dentition. Neglect can lead to a variety of problems, ranging from white spot surface lesions to fully engulfed carious lesions. Minimally invasive treatment should follow only dedicated preventive maintenance. The patient in this case underwent a minimally invasive procedure which preserved sound tooth structure. This preservation lends itself to better future treatment options as dental technology advances.

Acknowledgment:

The author declares no financial interest in the sale of any product referenced herein.

References

1. Kressin NR, Boehmer U, Nunn ME, Spiro A 3rd. Increased preventive practices lead to greater tooth retention. *J Dent Res* 2003;82(3):223-227.
2. Widstrom E. Prevention and dental health services. *Oral Health Prev Dent* 2004;2(Suppl1):255-258.
3. Greenwell L. Bleaching techniques in restorative dentistry: An Illustrated Guide. London, UK: Martin Dunitz, 2001:1-23.
4. Loesche WJ. Chemotherapy of dental plaque infections. *Oral Sci Rev* 1976;9:65-107.
5. Steinberg S. A paradigm shift for caries diagnosis and treatment—Part I: Diagnosis. *J Pract Hygiene* 2004;13(2):27-30.
6. Christensen GJ. The advantages of minimally invasive dentistry. *J Am Dent Assoc* 2005;136(11):1563-1565.
7. White JM, Eakle WS. Rationale and treatment approach in minimally invasive dentistry. *J Am Dent Assoc* 2000;131(9):1250,1252.
8. Rainey JT. Understanding the applications of microdentistry. *Compend Contin Educ Dent* 2001;22(11A):1018-1025.
9. Brantley CF, Bader JD, Shugars DA, Nesbit SP. Does the cycle of restoration lead to larger restorations? 1995;126(10):1407-1413.
10. Lutz F, Krejci I, Besek M. Operative dentistry: The missing clinical standards. *Pract Periodont Aesthet Dent* 1997;9(5):541-548.
11. Additional aids to the remineralization of tooth structure. In: Reynolds EC, Walsh IJ. *Preservation and Restoration of Teeth*. 2nd ed. 2005:111-118.
12. Manhart J, Mehl A, Schroeter R, et al. Bond strength of composite to dentin treated by air abrasion. *Oper Dent* 1999;24(4):223-232.
13. Berry EA 3rd, Ward M. Bond strength of resin composite to air-abraded enamel. *Quintessence Int* 1995;26(8):559-562.
14. Rosenberg SP. Air abrasion in the aesthetic restorative practice. *Pract Periodontics Aesthet Dent* 1999;11(7):843-844.
15. Bryant CL. The role of air abrasion in preventing and treating early pit and fissure caries. *J Can Dent Assoc* 1999;65(10):566-569.
16. Okuda WH. Achieving optimal aesthetics for direct and indirect restorations with microhybrid composite resins. *Pract Proced Aesthet Dent* 2005;17(3):177-184.
17. Mitra SB, Wu D, Holmes BN. An application of nanotechnology in advanced dental materials. *J Am Dent Assoc* 2003;134(10):1382-1390.